



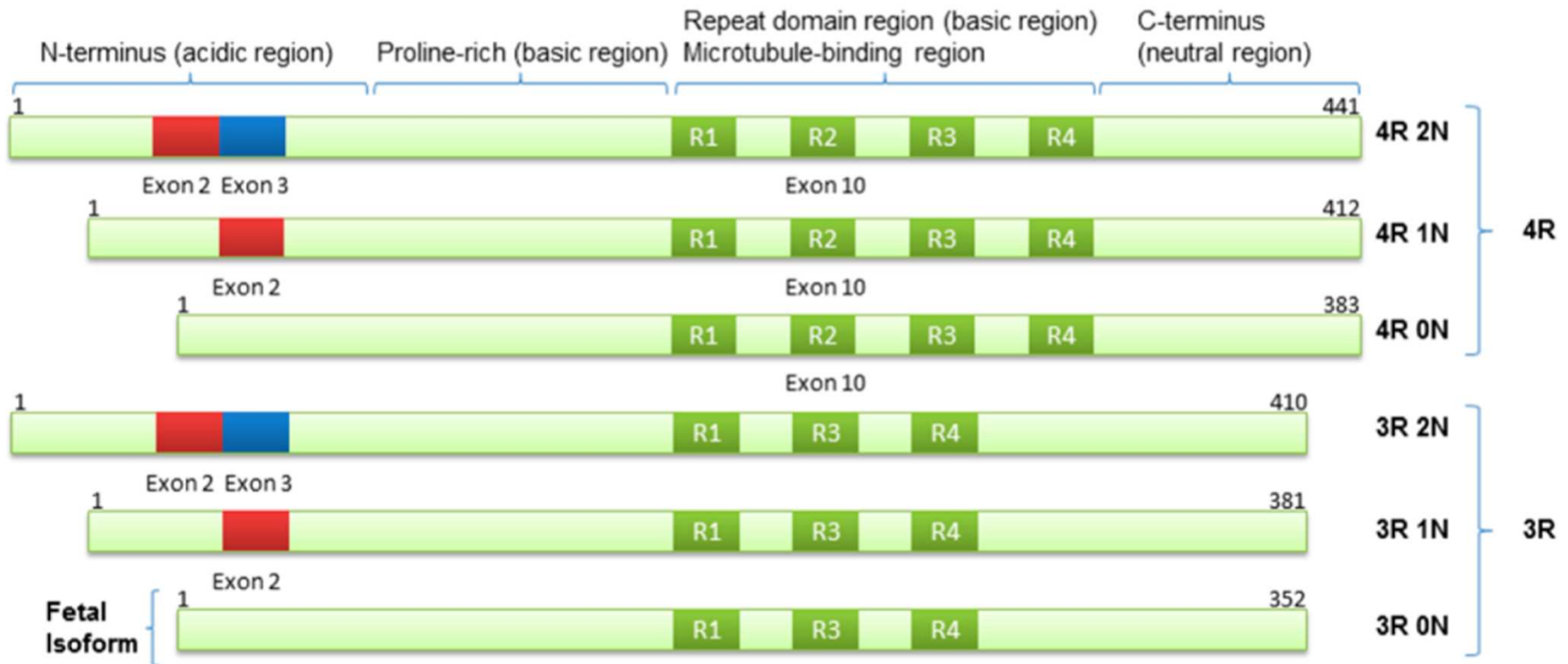
# Tauopathies et traceurs

Edouard Depardon

12 décembre 2015



# La protéine tau



# Protéine Tau & Tauopathie

Neurone sain

Stabilisation par la protéine Tau

Microtubule

Neurone malade

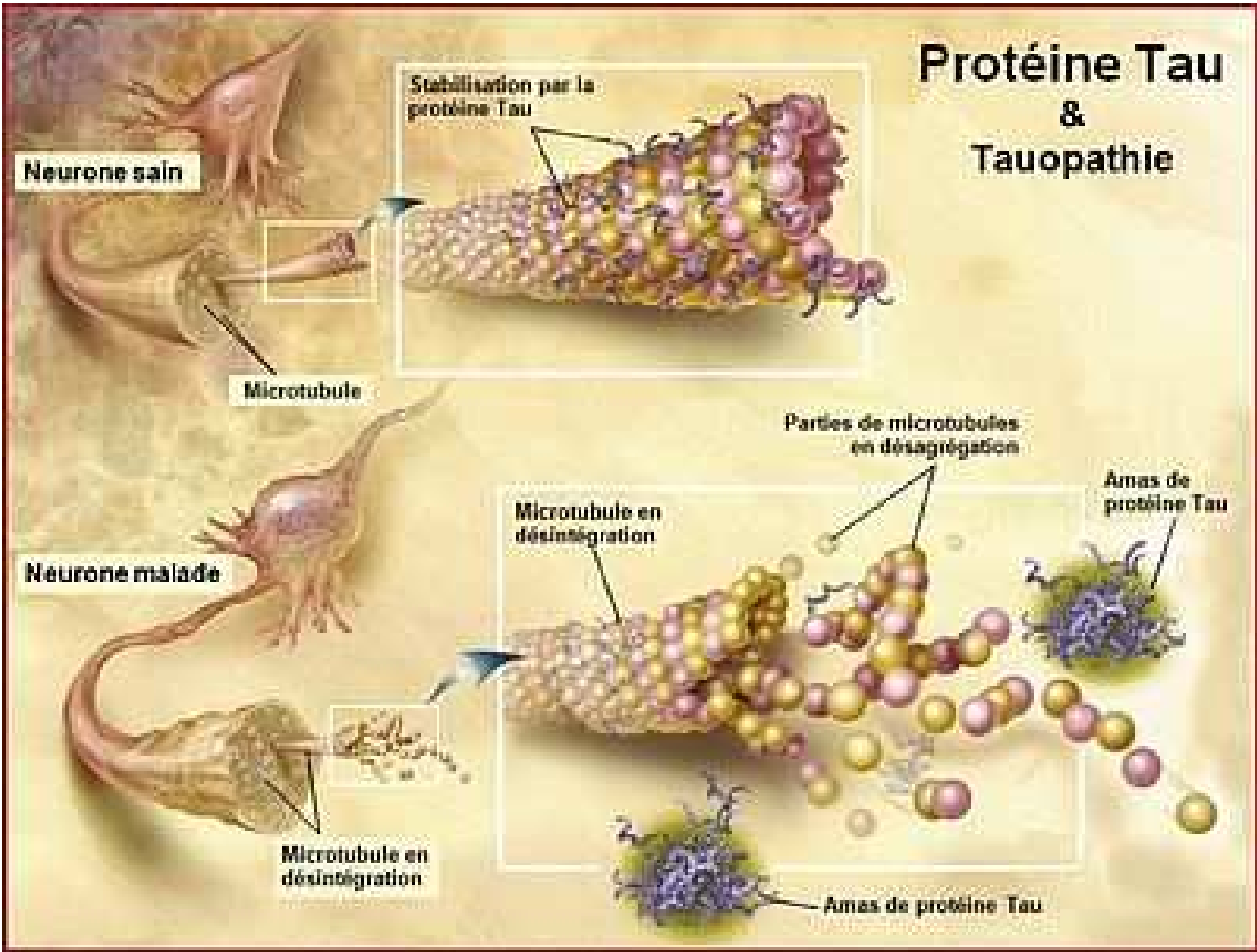
Microtubule en désintégration

Parties de microtubules en désagrégation

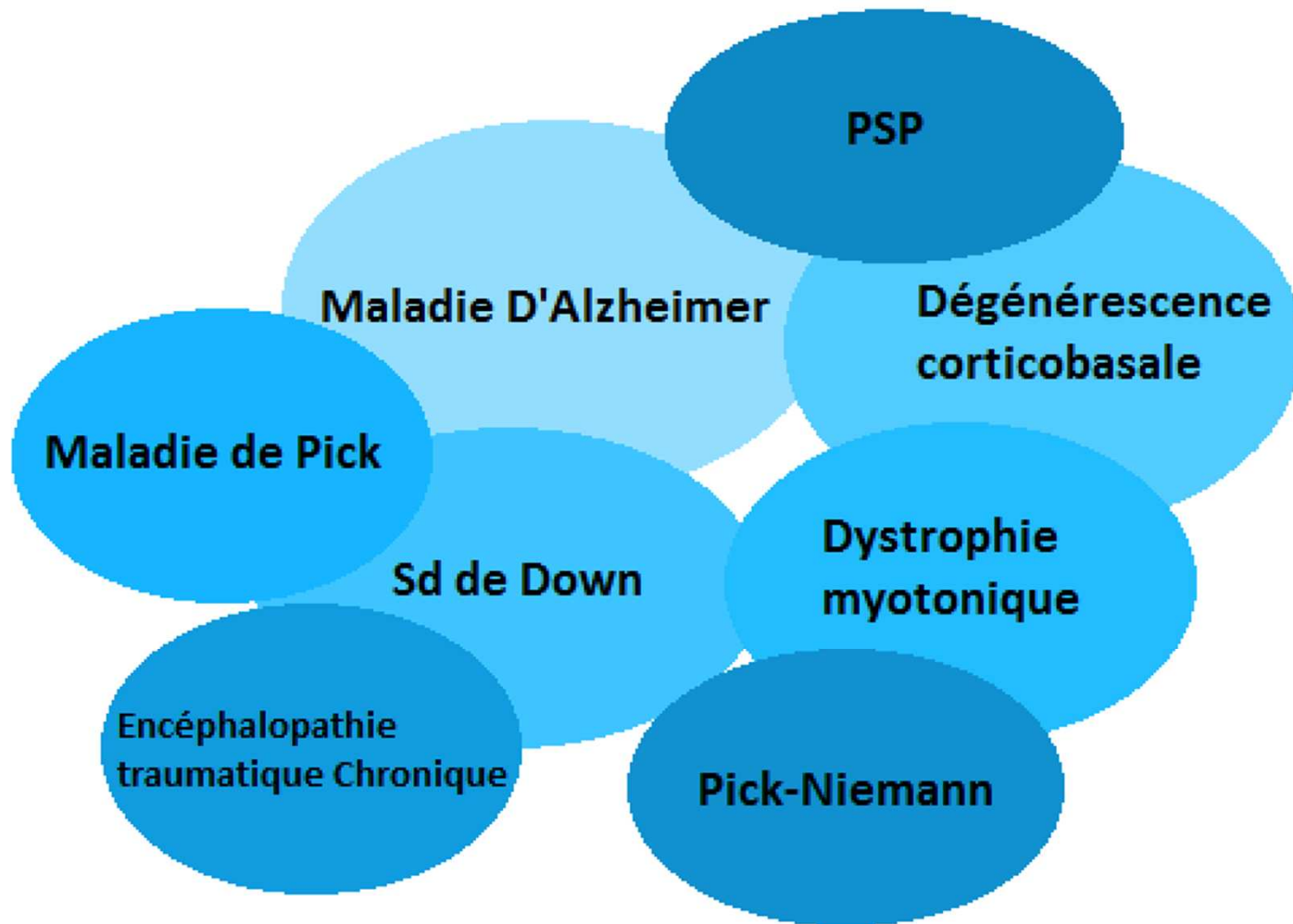
Amas de protéine Tau

Microtubule en désintégration

Amas de protéine Tau



# Tauopathies



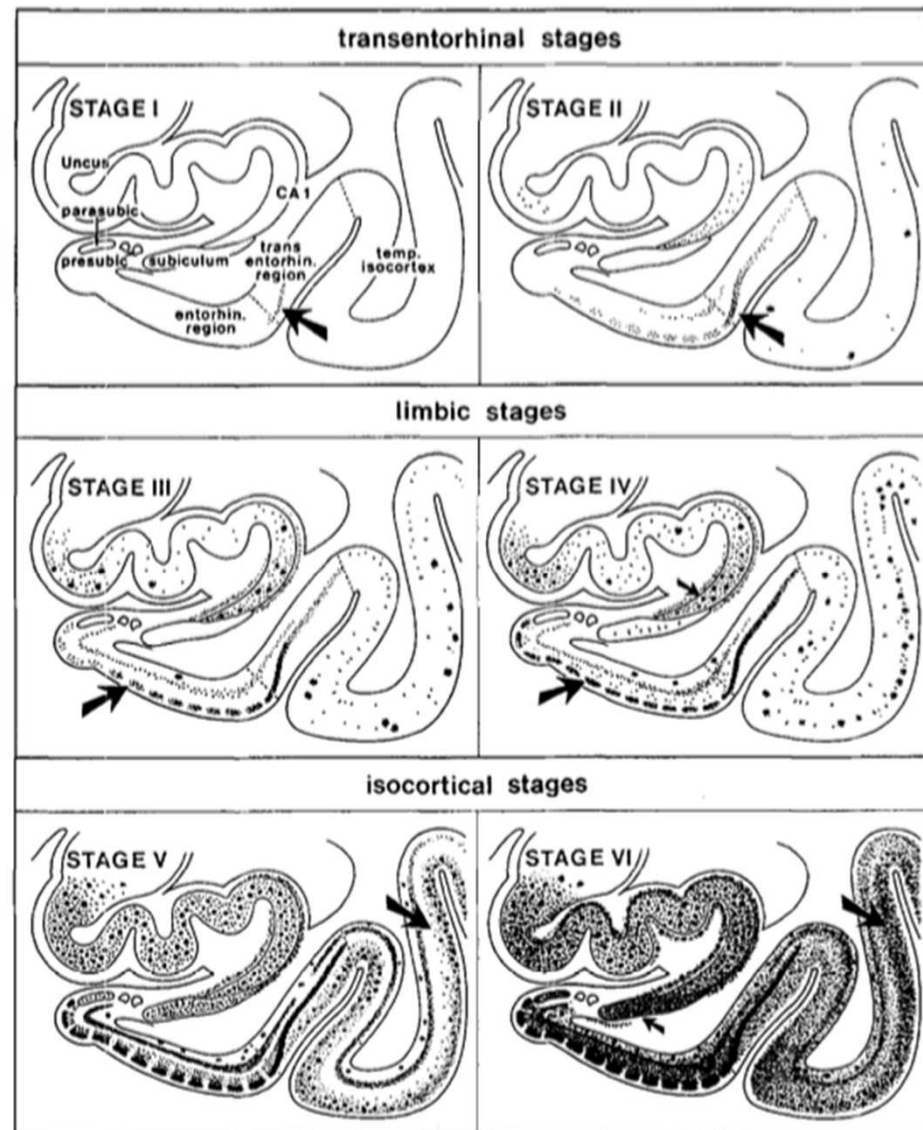
# Tauopathies

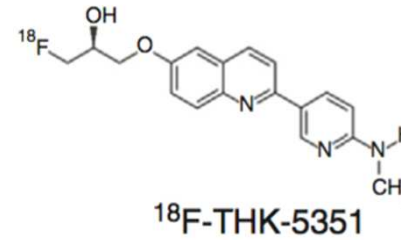
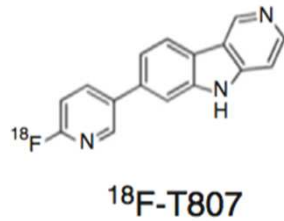
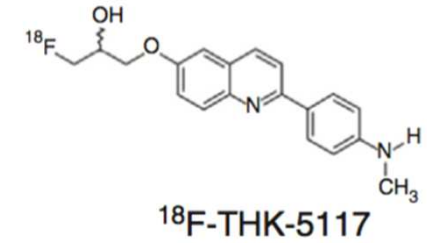
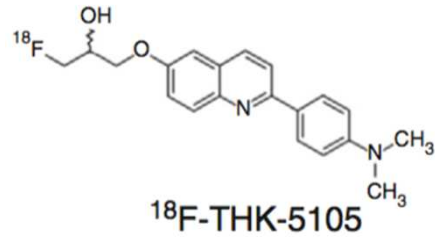
**Histopathological appearance of tau isoforms and conformations in different tauopathies**

Type	Tauopathy	Tau isoform	Histopathology	
			Electron microscope	Light microscope
Primary tauopathies	Progressive supranuclear palsy	4R	SF (& TF)	Tufted astrocytes; Globose tangles
	Corticobasal degeneration	4R	SF (& TF)	Astrocytic plaques
	Argyrophilic grain disease	4R	SF	Oligodendroglial coiled bodies; Limbic argyrophilic grains
	Pick's disease	3R	TF (& SF)	Pick's bodies
Secondary tauopathies	Myotonic dystrophy	Short 0N3R	N/A	Neurofibrillary tangles
	Alzheimer's disease	3R & 4R	PHF (& SF)	Neurofibrillary tangles
	Down Syndrome	3R & 4R	PHF (& SF)	Neurofibrillary tangles
	Chronic traumatic encephalopathy	3R & 4R	PHF (& SF)	Neurofibrillary tangles
	Niemann-Pick disease type C	3R & 4R	PHF (& SF)	Neurofibrillary tangles

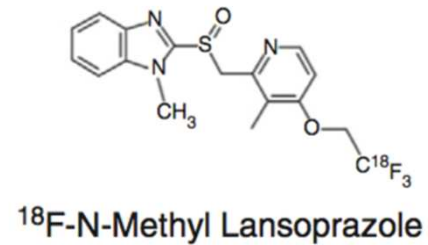
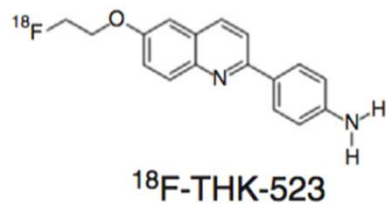
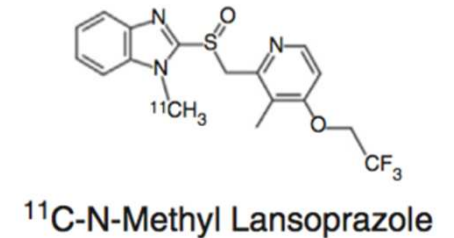
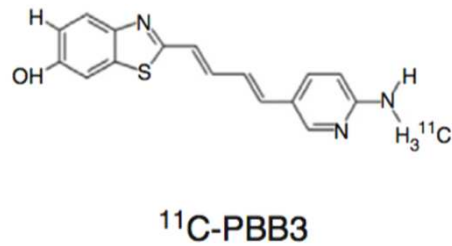
*Abbreviations.* 3R: three repeat; 4R: four repeat; PHF: paired helical filaments; SF: straight filaments; TF: twisted filaments; N/A data not available. Short 0N3R: the shortest isoform of Fetal tau (where N denotes the number of N-terminal inserts and R the number of microtubule binding domains).

# Dépôt de tau dans la Maladie d'Alzheimer: Braak





## La traceurs TEP de tau

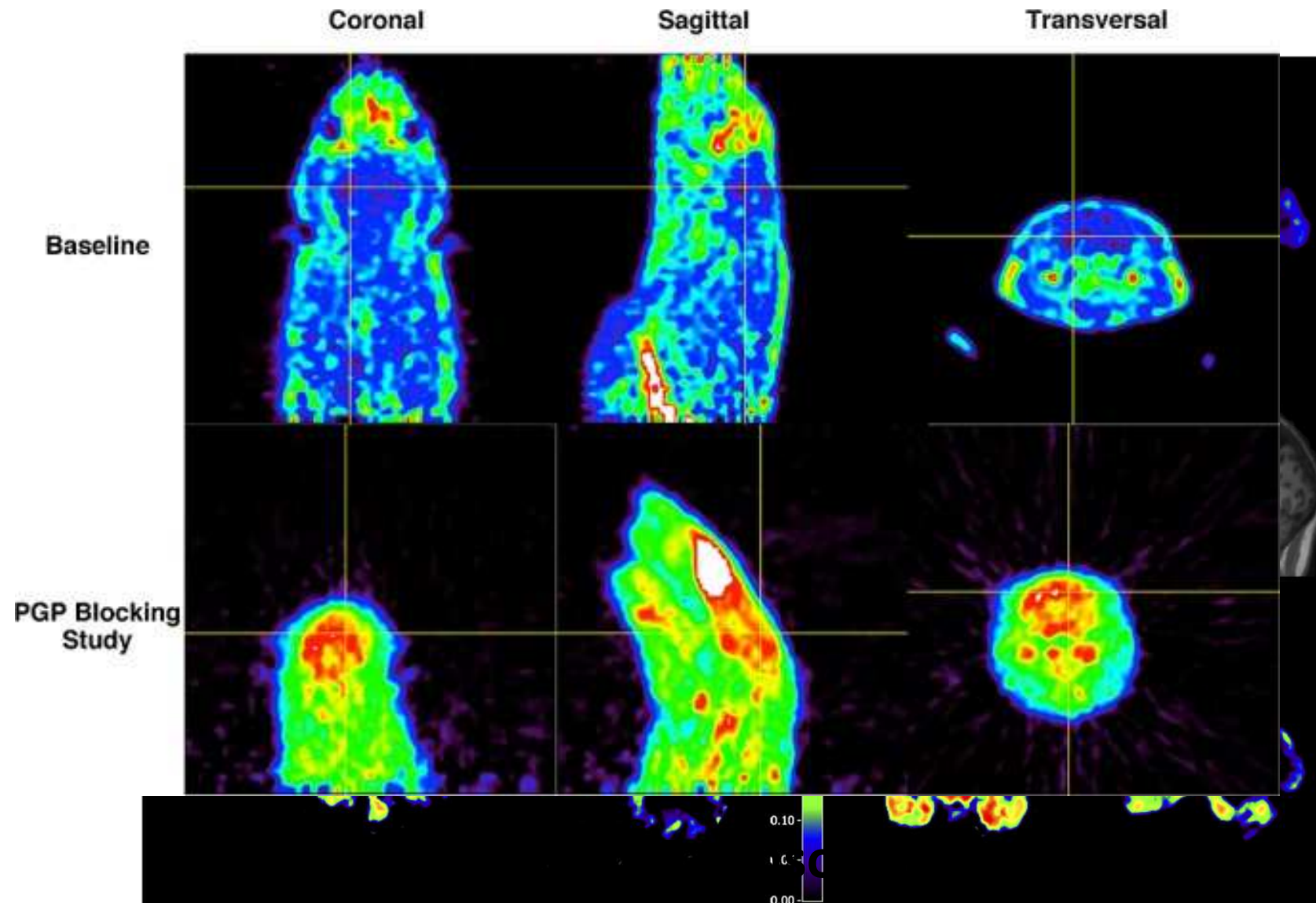


# Caractéristiques nécessaires d'un bon traceur tau

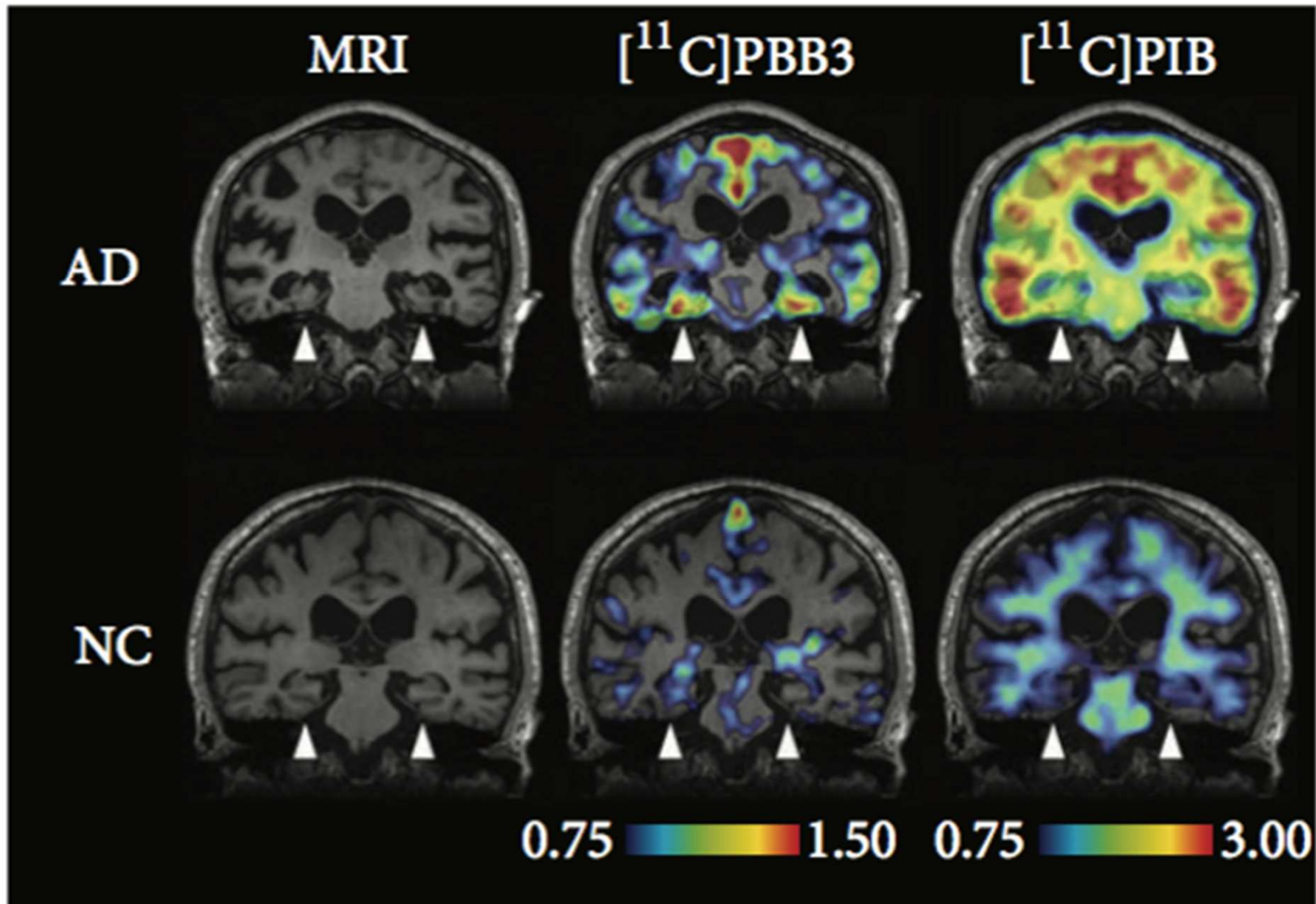
- Non toxique, lipophile: traverse la BHC
- Coefficient d'extraction sanguine élevée (éviter dégradation)
- Faible affinité pour les cible non spécifiques
- Forte affinité pour les cibles spécifiques
- Isotope utilisé avec  $\frac{1}{2}$  vie assez « longue »



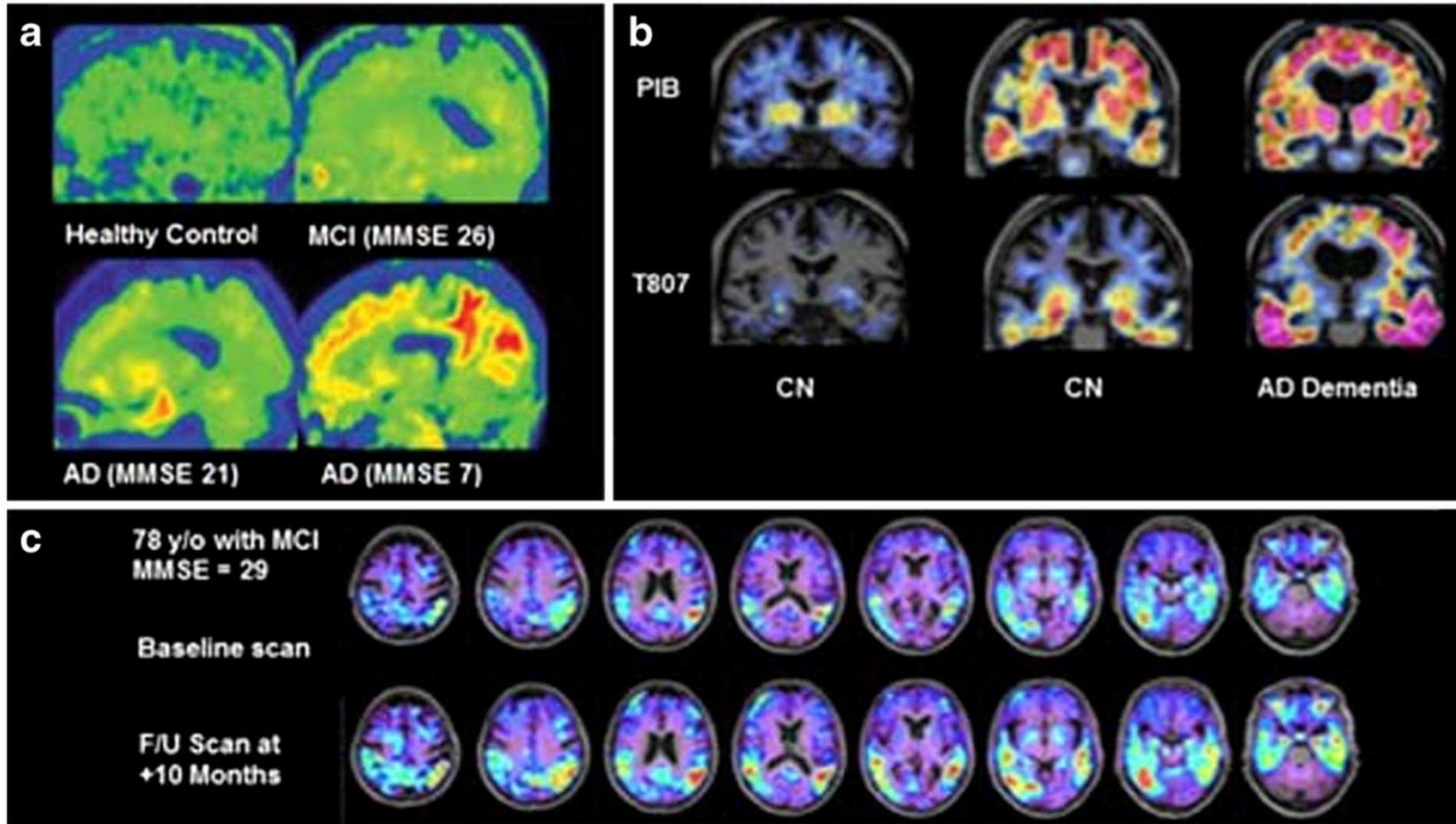
# Les premiers traceurs



# $^{11}\text{C}$ -PBB3

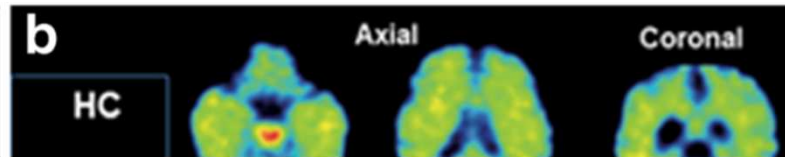
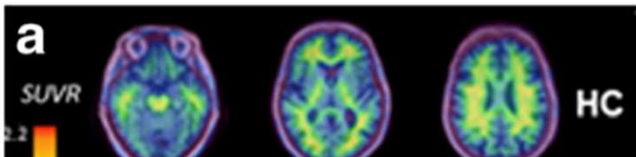


# $^{18}\text{F}$ -AV-1451 (a.k.a $^{18}\text{F}$ -T807)

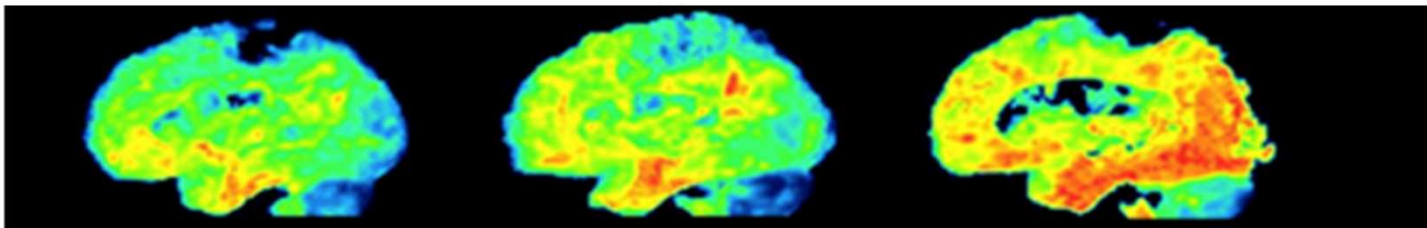
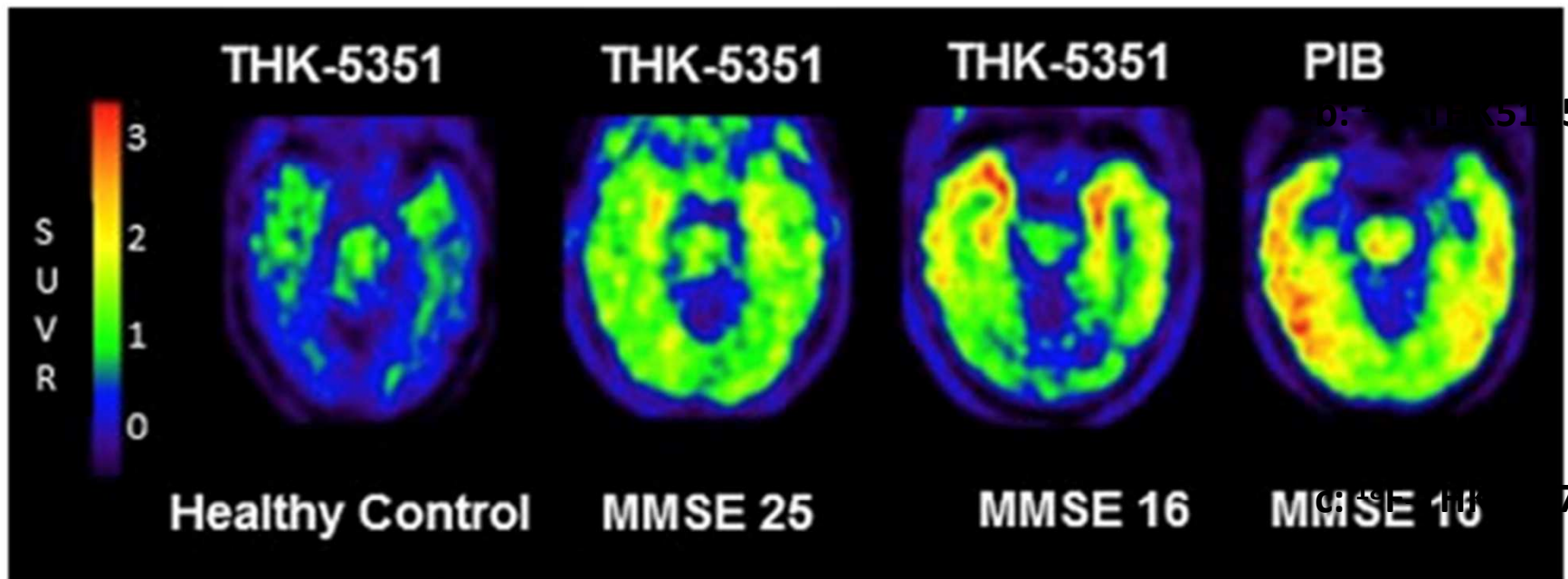




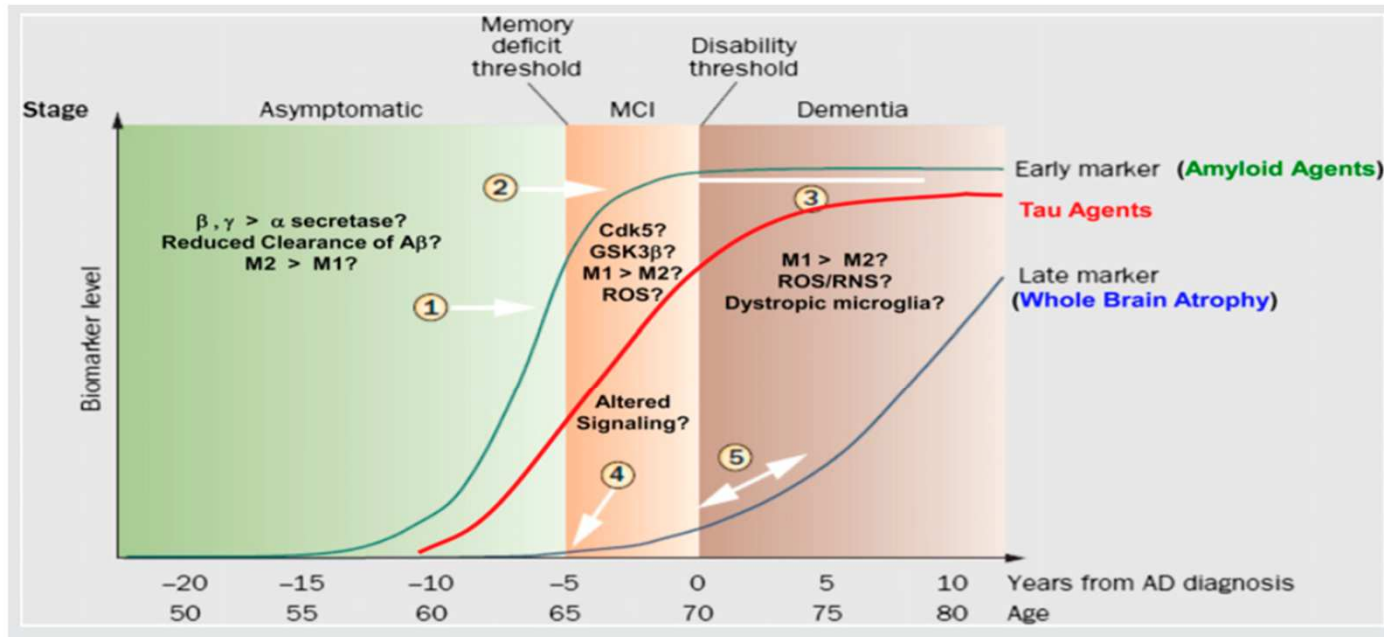
# La série THK ( $^{18}\text{F}$ -THK...)



a:  $^{18}\text{F}$ -THK523

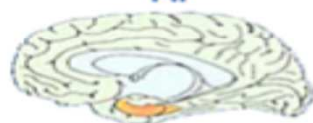

# Conclusion



Tau pathology correlates with symptoms of dementia

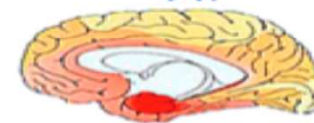
Clinically silent  
transentorhinal stages  
I-II



Incipient AD  
limbic stages  
III-IV




Fully developed AD  
neocortical stages  
V-VI

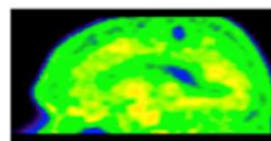


↑ Staining intensity of NFT

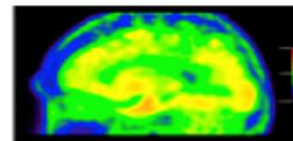
[18F]-T807 PET images demonstrate increased tracer uptake with disease progression



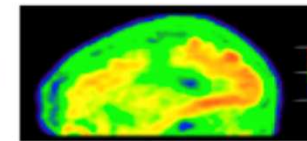
Healthy controls (n=3)




Amyloid+  
MCI, MMSE=26



Amyloid+  
Mild AD, MMSE=21



Severe AD, MMSE=7



SUVR

# Bibliographie

- Ariza, Manuela, Hartmuth C. Kolb, Dieder Moechars, Frederik Rombouts, and José Ignacio Andrés. “Tau Positron Emission Tomography (PET) Imaging: Past, Present, and Future.” *Journal of Medicinal Chemistry* 58, no. 11 (juin 2015): 4365–82. doi:10.1021/jm5017544.
- Braak, Heiko, Irina Alafuzoff, Thomas Arzberger, Hans Kretschmar, and Kelly Del Tredici. “Staging of Alzheimer Disease-Associated Neurofibrillary Pathology Using Paraffin Sections and Immunocytochemistry.” *Acta Neuropathologica* 112, no. 4 (2006): 389–404. doi:10.1007/s00401-006-0127-z.
- Braak, Heiko, and Eva Braak. “Staging of Alzheimer’s Disease-Related Neurofibrillary Changes.” *Neurobiology of Aging* 16, no. 3 (May 1, 1995): 271–78. doi:10.1016/0197-4580(95)00021-6.
- Dani, M., D. J. Brooks, and P. Edison. “Tau Imaging in Neurodegenerative Diseases.” *European Journal of Nuclear Medicine and Molecular Imaging*, November 16, 2015, 1–12. doi:10.1007/s00259-015-3231-2.
- Lemoine, Laetitia, Laure Saint-Aubert, Amelia Marutle, Gunnar Antoni, Jonas P Eriksson, Bernardino Ghetti, Nobuyuki Okamura, Inger Nennesmo, Per-Göran Gillberg, and Agneta Nordberg. “Visualization of Regional Tau Deposits Using 3H-THK5117 in Alzheimer Brain Tissue.” *Acta Neuropathologica Communications* 3 (July 2, 2015). doi:10.1186/s40478-015-0220-4.
- Mach, Robert H. “New Targets for the Development of PET Tracers for Imaging Neurodegeneration in Alzheimer Disease.” *Journal of Nuclear Medicine* 55, no. 8 (August 1, 2014): 1221–24. doi:10.2967/jnumed.114.127811.
- Villemagne, Victor L, and Nobuyuki Okamura. “Tau Imaging in the Study of Ageing, Alzheimer’s Disease, and Other Neurodegenerative Conditions.” *Current Opinion in Neurobiology* 36 (février 2016): 43–51. doi:10.1016/j.conb.2015.09.002.
- Villemagne, Victor L., and Nobuyuki Okamura. “In Vivo Tau Imaging: Obstacles and Progress.” *Alzheimer’s & Dementia: The Journal of the Alzheimer’s Association* 10, no. 3 (June 1, 2014): S254–S264. doi:10.1016/j.jalz.2014.04.013.